

Case History

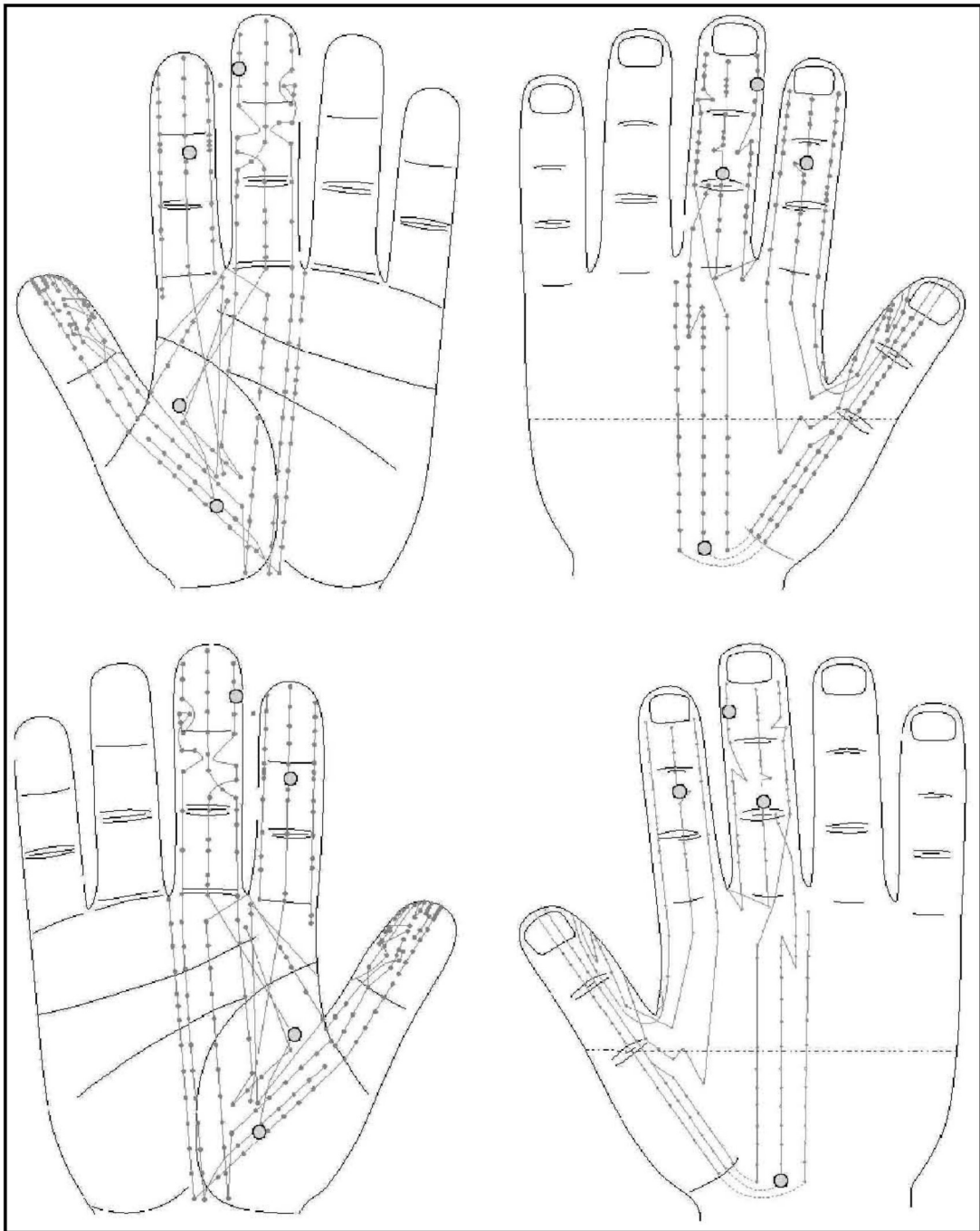
Section I : Chinese Acupressure

M.P. Khemka

Case No. - (1)

Continous Hiccup

Therapist	: Sri. M.P. Khemka	Sleep	: 11.00 pm to 7.00 am
Patient	: Mr. Amit Tiwari	Thirst	: 2-1/2 Ltrs.
Age	: 30 yrs.	Urine	: D-2-3 times
Address	: Tagore Town	App.	: Less
Phone.no	: 9455221709	Taste	: Sweet
Past History	: Rt ear operated - 12 yrs. ago	Stool	: Constipation
Symptoms	: Continue hiccup - 1 Week	Emotion	: Normal
Treatment	: P 6, TW 6, GB 34, Liv 3, 13, 14 (L & R) YBM		
15.3.18	St 43 (Original) Y B M.		
	UB 17 - Y B M		
Result	: 100% Relief		
17.3.18	Patient एक सप्ताह से परेशान थे करीब 6000 का test करा चुके थे सब normal Report आया allopath, homeopath और ayurved दवायें ले चुके थे लेकिन आराम नहीं मिला। यहाँ Pt. लगाने के 5-10 मिनट बाद ही उन्हें पूरा आराम मिल गया।		



Case No.- (2)

Gastric & Acidity

Therapist : Sri. M.P. Khemka
Patient : Smt. Prabhjot Kaur
Age : 38 yrs.
Address : 2c / 23 New Rohtak Road New Delhi
Phone.no : 9582797536
Past History : MRI - Cervical Spine -12/08/17

Sleep	:	Normal
Thirst	:	2 Ltrs.
Urine	:	D-5-6 times
App.	:	Normal
Taste	:	Sweet
Stool	:	Constipation
Period	:	Normal 4-5 day
Emotion	:	Depression

- Cervical lordosis is straightened.
- Mild posterior disc herniations with thecal sac indentation are seen at L3/L4 & L4/5 levels.
- Partial disc desiccation changes are seen at afore mentioned level in the form of subtle loss of T 2 W hyper intense signal intensity.

U/S (09/03/18)

Liv - hepatomegaly and II fatty infiltration.

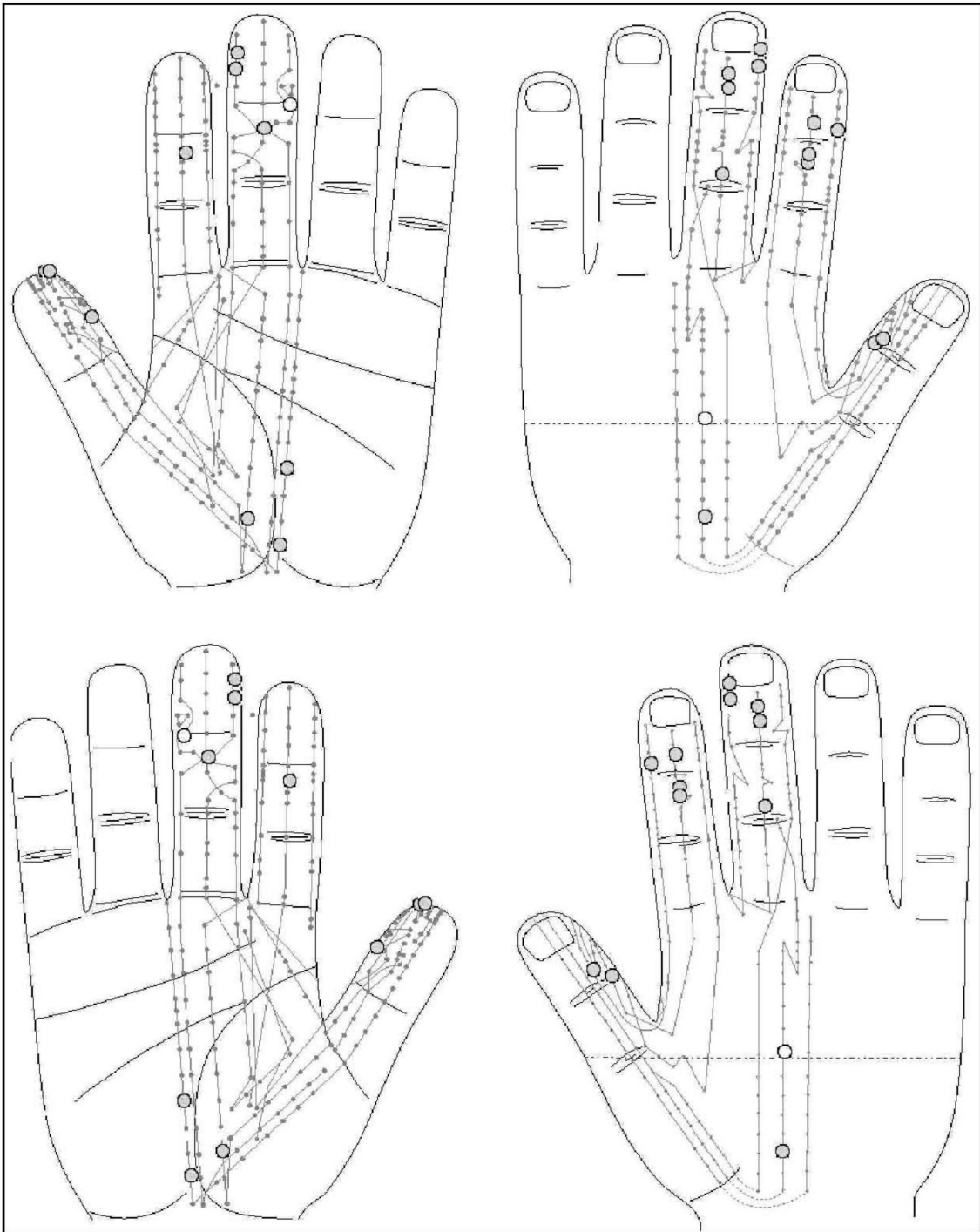
GB - multupal calculi (3-4 mm)

MRI - Brain (15/05/17) Normal

Symptoms : 1. Vertigo - Jan 2018 - frequent urination & cold feeling during vertigo.
2. Tinnitus - Mostly Rt Ear - 3 month
3. Tingling sensation in black of head.
4. Restlessness & anxiety.
5. Pain in eyes & watery.
6. Numbness in soles.
7. Weakness & tiredness.
8. GB stone
9. Gastric & Acidity - during vertigo.
10. Palpitation - Mostly sleeping time.
11. Swelling in Rt side neck.
12. Rashes
13. Sometime low grade fever

Treatment : Liv 2, GB 20, 16, UB 18 L/R YBM
19.4.18 K 3, UB 23 L/R WBM
TW 3, 5, 17, GB 2, 41, 43, Liv 2, Li 4 L/R - YBM
P 6, Tw 6, GB 34, Liv 3 YBM L/R
Sp 6, St 21, 44, 45, CV 13, 10 Y B M L/R (20/04/18)

Result : 1. 60 % Relief (vertigo)
20.4.18 2. 10% Relief
3. 40% Relief
4. 20% Relief
5. 40% Relief
6. 80% Relief
7. 50% Relief
8. GB stone
9. Partial Relief
10.20% Relief
11. ---
12. ---
13.Relief



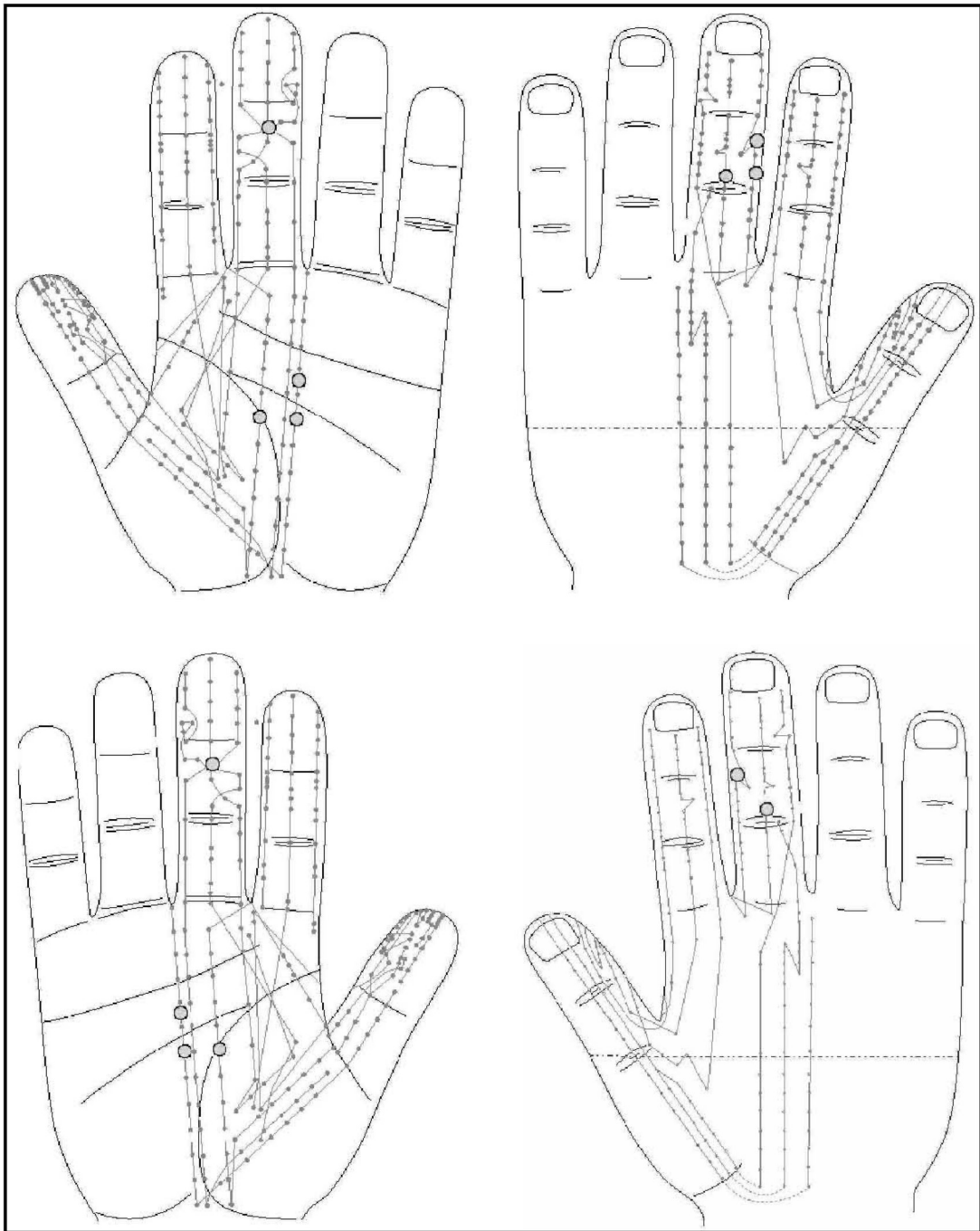
Case No.- (3)

Epigastric Area Pain

Therapist : Sri. M.P. Khemka
Patient : Smt. Shashmita Singh
Age : 34 yrs.
Address : Tagore Town Allahabad
Phone.no : 9936833266
Symptoms : 1. Epigastrium Pain (20 Yrs)
2. Gas Formation with Belching - 20 Yrs.
Treatment : St 25, 36.1/2, 39, CV 6, GB 34
23.3.18 Sp 6, Liv 3, CV 8 (L&R) YBM
Result : 1. Relief 100%
26.3.18 2. Relief 100%

Sleep	:	—
Thirst	:	—
Urine	:	—
App.	:	—
Taste	:	—
Stool	:	—
Period	:	—
Emotion	:	—

20 वर्षों से तकलीफ थी लेकिन Pts लगने के 15 मिनट बाद ही रोगी ने पूर्णतः आराम बताया। कहने लगी इतना आराम मुझे जीवन मे (20 वर्षों मे) नहीं मिला था।



Case No.- (4)

Writer's cramp.

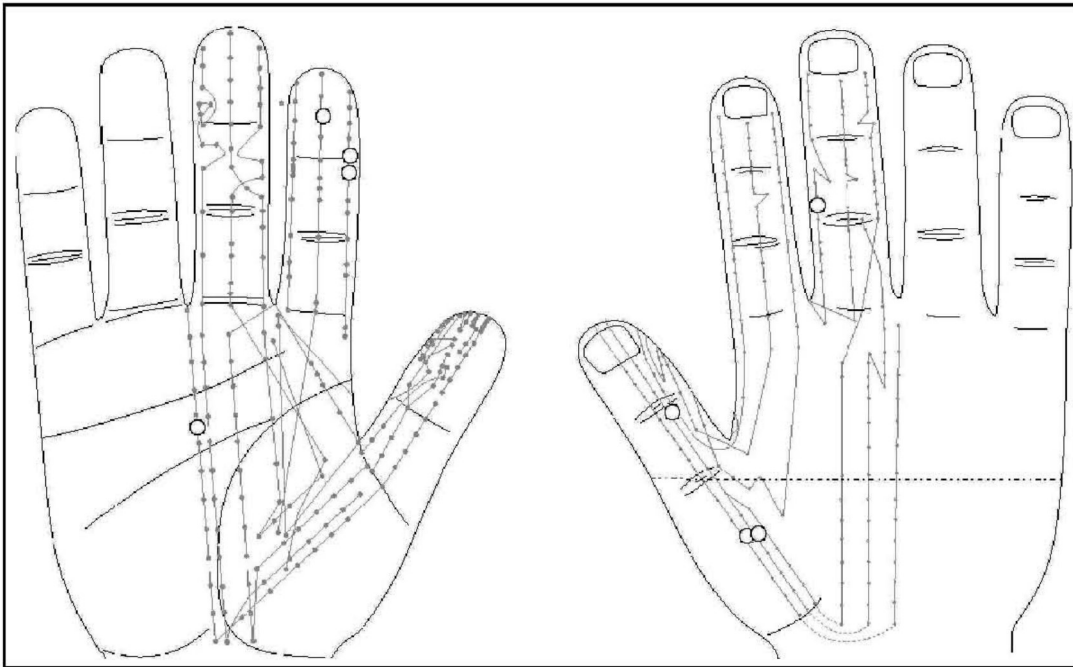
Therapist : Sri. M.P. Khemka
Patient : Mr. Ratan Bihari
Age : 54 yrs.
Address : Uchawaghari, Rajapur, Allahabad
Phone.no : 9415785882
Symptoms : 1. Writer's cramp.
Rt hand - 8 month

Sleep : 11.00 pm to 5.00 am
Thirst : 2 Ltrs.
Urine : D-4-5 times
App. : Normal
Taste : Normal
Stool : Normal
Emotion : Normal

Treatment : Lu 7, 9, UB 13, GV 12, CV 6, St 36
2.4.18 UB 10, P 8 - (R) WBM

Result : 1. Relief 50%

14.04.18 पहले पेन पकडने में दिक्कत होती थी पेन फिसलती थी सीधे लिख नहीं पाते थे। Treatment के बाद पेन पकड कर लिखने लगे, लिखावट भी साफ हुई।



Case No.- (5)

Muscle pain

Therapist : Sri. M.P. Khemka

Patient : Smt. Manju Singh

Age : 34 yrs.

Address : Allahpur

Phone.no : 9450632013

Past History : MRI - Lumbo- sacral spine (01.09.16)

1. Transitional lumbo - sacral junction is seen (sacralized L 5 with pseudo - arthrosis).
2. Mild marginal osteophytic lipping is seen at L 3 & L 4 vertebral level.
3. Small hemangioma is seen in L 1 vertebral body.
4. Degenerative disc dessication is seen at L 3-4 & L 3-4 levels with reduced L 4-5 disc height.
5. Schmorl's node formation is seen at multiple end - plates.
6. Mild central and Rt para central disc protrusion is seen at L 3 - L 4 level causing thecal sac indentation.
7. Broad- based central and Rt para central protrusion is seen at L 4-5 level encroaching on Rt eateral Lecess with indentation on thecal sac & traverging Rt L 5 neve roots.
8. Both sacro- iliac joints show subtle articular irregularities at iliac aspect of both sacro- iliac joints with subarticular, Mild fatty nerve signal changes.
9. Straightening of cervical lordosis.

Sleep	: 10 pm to 6 am
Thirst	: 12-13 glass
Urine	: D-12, N-1 times
App.	: Normal
Taste	: Sweet
Stool	: Normal
Period	: Timely 3 day flow
Emotion	: Calm

-Blood (01.09.16)

ESR - 35

8.09.16 TSH- 6.67 (0.35-5.50)

25.03.17 MCH- 25 (26.7-31.9)

MCHC- 31.7 (32-36)

RDW- (8-12)

TSH- 4.18

15.04.17 Temp:- 98.2

- Symptoms** : 1. Muscle pain in lower (U B Meri) back to legs (5-6 days)
01.09.2017 2. Movement problem in knees & pain. (ex. pain during walking & sitting.)
3. Burning & tingling sensation in legs, something Numbness.
4. Pain in lumber to back side of Rt leg.
- Treatment** : P 6, Sp 6, St 21, 44, 45, CV 13, 12, 10 (L&R) YBM
01.09.2017 Si 3, UB 62, 54 (L&R) WBM
K 3, 7, CV 4, 6, GV 4, UB 23, 47 (L&R) WBM
: UB 60, 57, 54, 51, GB 34, 30, GV 3 (L&R) WBM
- Result** : 1. 80% Relief
23.04.2018 2. 80% Relief
3. Relief
4. Relief

रोगिणी ने बताया कि उनका M.R.I. Report देख कर डा हसते थे कि आपका कोई इलाज नहीं हो सकता सिवा आपरेशन के दिल्ली जाकर आपरेशन करवा लो। रोगिणी यहाँ पर 1 Sep 2017 को आई वो उठ – बैठ नहीं पा रही थी। चलती भी थी बहुत दर्द होता था। यहाँ धीरे धीरे आराम मिलता गया और आज उन्होंने बहुत खुश होकर बताया कि मुझे बहुत आराम है। अब घुटना मुडने लगा। मैं जमीन पर भी आराम से बौठ कर उठ जाती हूँ मैं बिलकुल ठीक हो गई हूँ।

