

Section II : Ayurvedic Acupressure

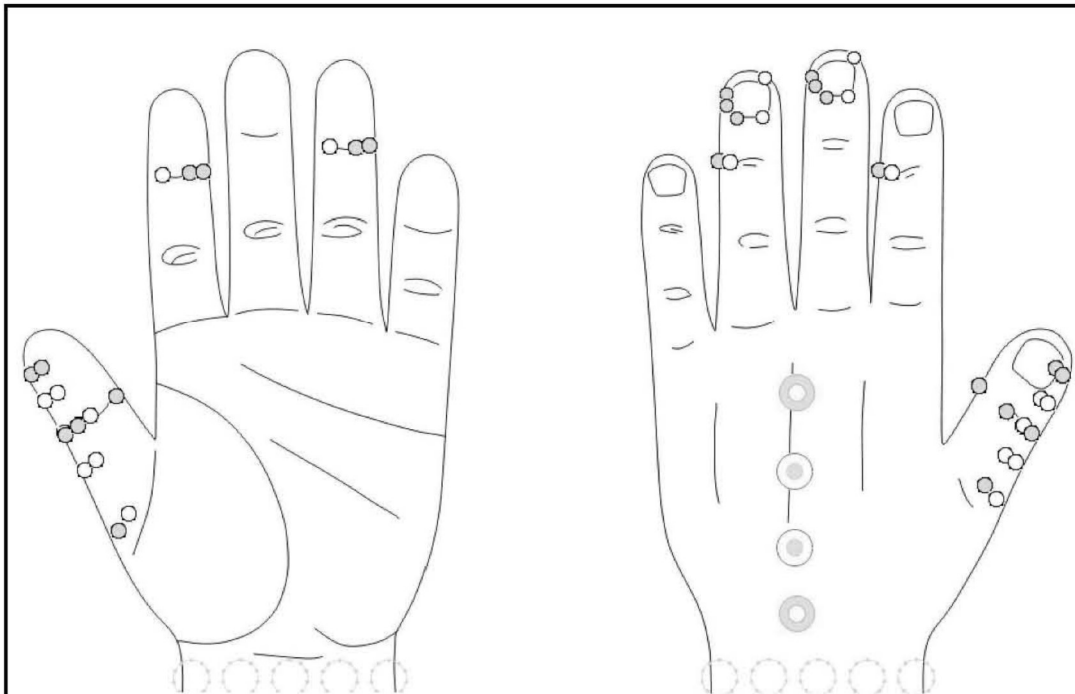
J P Agrawal

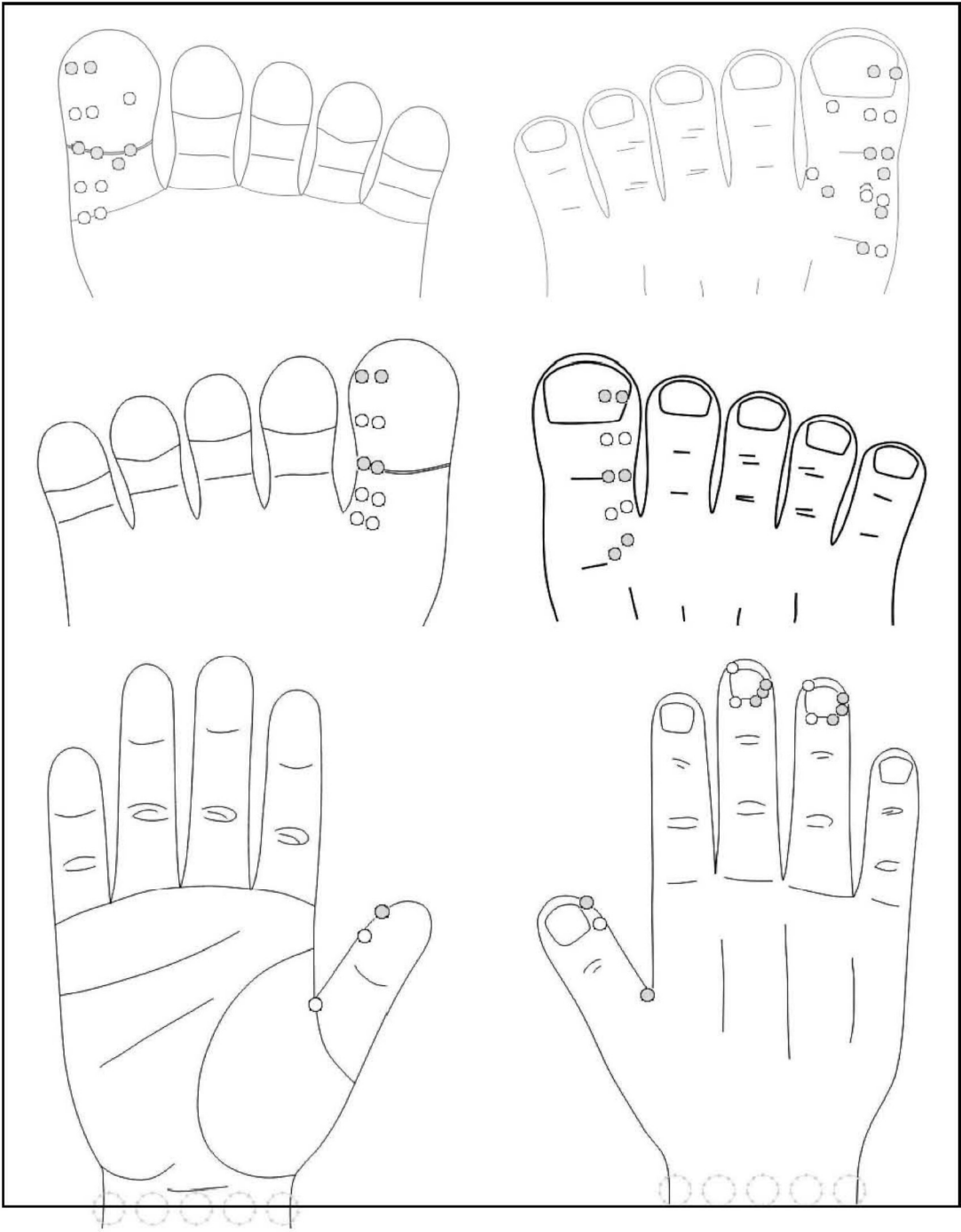
Case No.- (1)

Node in Head & breast Pain with Multiple problems

<p>Therapist : Shri J.P. Agarwal</p> <p>Patient : Smt. Sheela Tripathi</p> <p>Age : 48 years</p> <p>Address : 126 Karbala, Allahabad</p> <p>Phone : 7505234028</p> <p>Past History : Appendix (Op-20 years)</p> <p>& Reports</p> <p>Symptoms : 1 Headache (2 years) Sometimes Red eyes.</p> <p>15.03.2017 -Rt. Side Node in head</p> <p>2 Rt. Breast pain</p> <p>3 Calf Muscles pain (2 months)</p> <p>4 Gastric Problem (13 years) -belching</p> <p>5 Less Appetite (1 years)</p> <p>6 On calcium medicine (11 years)</p> <p>05.04.2017 7 Lt. Side Toe No. 6 to Lumbar pain</p> <p>02.06.2017 8 Itching in face & Hand due to black patches in hand.</p> <p>Treatment :</p> <p>15.03.2017 1. ✕Lt. Palm - 2, 3 ↓ 1, 4 ↑</p> <p>2. Toe No (0) 4/5, 1/8 RLVM - 2, 4, 5, 7, 9 ↓ 0, 1, 3, 6, 8 ↑</p> <p>3. Toe No (9) 2/3, 6/7 RLVM - 2, 4, 5, 7, 9 ↓ 0,1,3,6,8 ↑</p> <p>4. Lt. Thumb 2/3 RLVM - 4, 5, 9 ↓ 0, 3, 6 ↑</p> <p>5. Rt.Thumb 4/5 RLVM - 4, 5, 9 ↓ 0, 3, 6 ↑</p> <p>05.04.2017 6 Fno. 9 V jt. - 2, 4, 5, 9 ↓ 0, 3, 7 ↑</p> <p>7 Fno. 3, 6 V jt. - 2, 3, 6 ↓ 1, 7 ↑</p>	<p>Sleep : 10.30 pm to 5.00 am</p> <p>Thirst : 7-8 glass</p> <p>Urine : D-5-6 times</p> <p>App. : Less</p> <p>Taste : Bitter</p> <p>Stool : Normal</p> <p>Period : —</p> <p>Emotion : Norma</p>
---	---

	8	Toe No 9 Smp 2 (3 & 9)	- 2, 4, 5 ↓ 3, 7 ↑
02.06.2017	9	☆ NCH (5, 6, 7,8)	- 2, 3, 6 ↓ 1, 8 ↑
Result	:		
28.06.2017	:	1. 70% Relief	
11.01.04		2. Relief	
		3. Relief	
		4. Relief	
		5. Relief	
		6. ---	
		7. Relief	





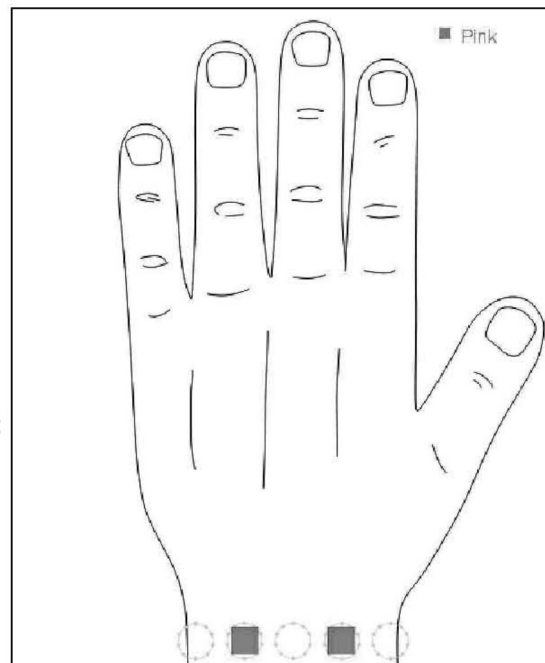
Case No.- (2)

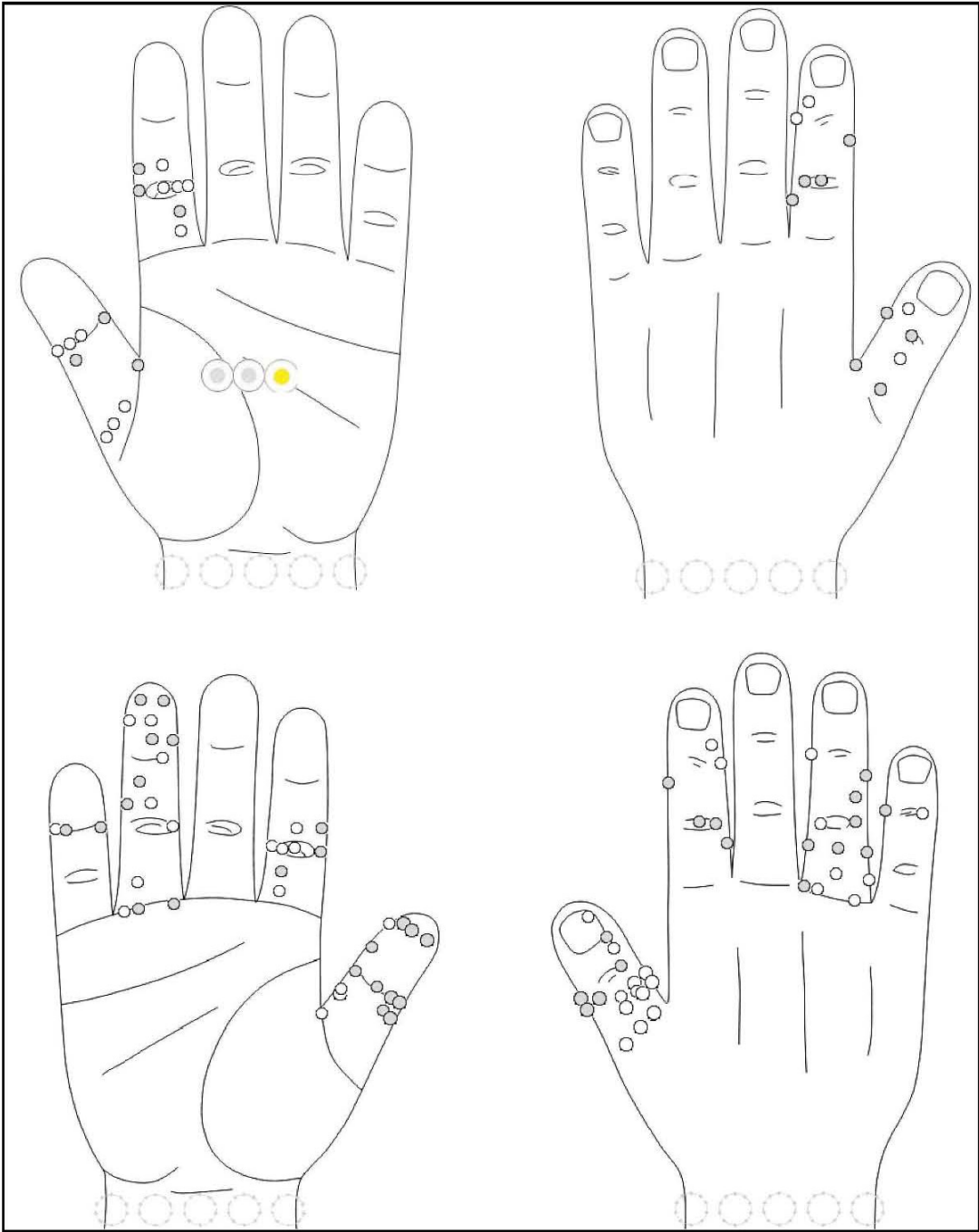
Surgery by Acupressure (glass piece in palm)

Therapist	: Shri J.P. Agarwal	Sleep	: 11.00 pm to 6.00 am
Patient	: Smt. Manju Jain	Thirst	: 3 Ltrs.
Age	: 48 years	Urine	: D-4-6, N-1 times
Address	: 225A/108/ 2G Patel Nagar, Meerapur, Allahabad	App.	: Normal
Phone	: 8739057379	Taste	: Salty
Symptoms	: 1 Diabetes on med (2 days)	Stool	: Normal
01.03.2016	2 Rt. Palm and pus formation (2 months)	Emotion	: Normal
26.05.2016	3 F.no. 5 Palm side numbness (3 months)		
	4 Rt.Hand less gripping (1months)		
	5 Rt.Palm injury region (inner region stress) (2 months)		
	6 Both side hip region to high pinching (after Injection) (3 months)		
	7 Gastric Problem (10Years)		
	8 Bleeding Piles (6 years)		
22.07.2016	9 Itching on both Forearms near elbow (1months)		
02.01.2017	10 Itching in head (2 1/2 months)		
	11 Hair Falling (2 1/2 months)		
	12 Lt./Rt Groin region (Bone) Pain after injury (5 days)		
	13 Rt thumb base jt region - glass piece in X-ray		
08.02.2017	14 Rt. Knee jt pain (7days)		
	15 Rt. hand to Rt. side chest pain -Pain radiates Rt. thumb to hand &Chest.		
Treatment	: 1. Both IF P jt.	-	4, 9 ↓ 0, 2, 3 ↑
01.03.2016	2. Lt. Thumb Both jts	-	4, 5, 9 ↓ 0, 2, 3 ↑
	3 ★ Du, Pn, St Corr.-	-	●
	4 Rt. Thumb 7,8,9,spm	-	4, 5, 9 ↓ 0, 2, 3 ↑
	5 Both Thumb 6th spm	-	4,5 ↓ 3, 6 ↑

	6	F.no.3,4,5 3rd spm	- 2, 3 ↓1, 4 ↑
Treatment	:	1. Both IF P jt.	- 4, 9 ↓0, 2, 3 ↑
01.03.2016		2. Lt. Thumb Both jts	- 4, 5, 9 ↓0, 2, 3 ↑
		3 ☆ Du, Pn, St Corr.-	- ●
		4 Rt. Thumb 7,8,9,spm	- 4, 5, 9 ↓0, 2, 3 ↑
		5 Both Thumb 6th spm	- 4,5 ↓3, 6 ↑
		6 F.no.3,4,5 3rd spm	- 2, 3 ↓1, 4 ↑
		7 Rt. SF Vjt. RF K jt.	- 2, 4, 5 ↓3, 7 ↑
		8 Lt. IF 0 spm	- 2, 4, 5 ↓3, 6, 7 ↑
		9 Rt IF 0 spm	- 2, 4, 5 ↓3, 6, 7 ↑
		10 Rt. RF 7,8 spm	- 2,4, 5, 7, 9 ↓0,1, 3, 6, 8 ↑
		11 ☆LMM 7, 8	- Pink Colour
2.11.16		12. Rt. Thumb 4/8 RLVM	- 2, 3, 6, 7, 9 ↓0, 1, 4, 5, 8 ↑

- Result** :
1. Diabetes
 2. Relief
 3. ---
 4. 40% Relief
 5. ---
 6. 60% Relief
 7. 40% Relief
 8. Relief
 9. 40% Relief
 10. 20% Relief
 11. 10% Relief
 12. ---
 13. Glass piece came out





Case No.- (3)

Rt side Hydrocele, Constipation & Gastric Problem

Therapist : Shri J.P. Agarwal
Patient : Suresh Prasad shah
Age : 59 years
Address : Mujaffarpur, Allahabad
Phone : 9430527572
Past History : Lt Side Hydrocele oprated (2010)
Symptoms :

Sleep	: 10.30 pm to 4.00 am
Thirst	: Increase
Urine	: D-3-4 times
App.	: Normal
Taste	: Sweet
Stool	: Constipation
Emotion	: —

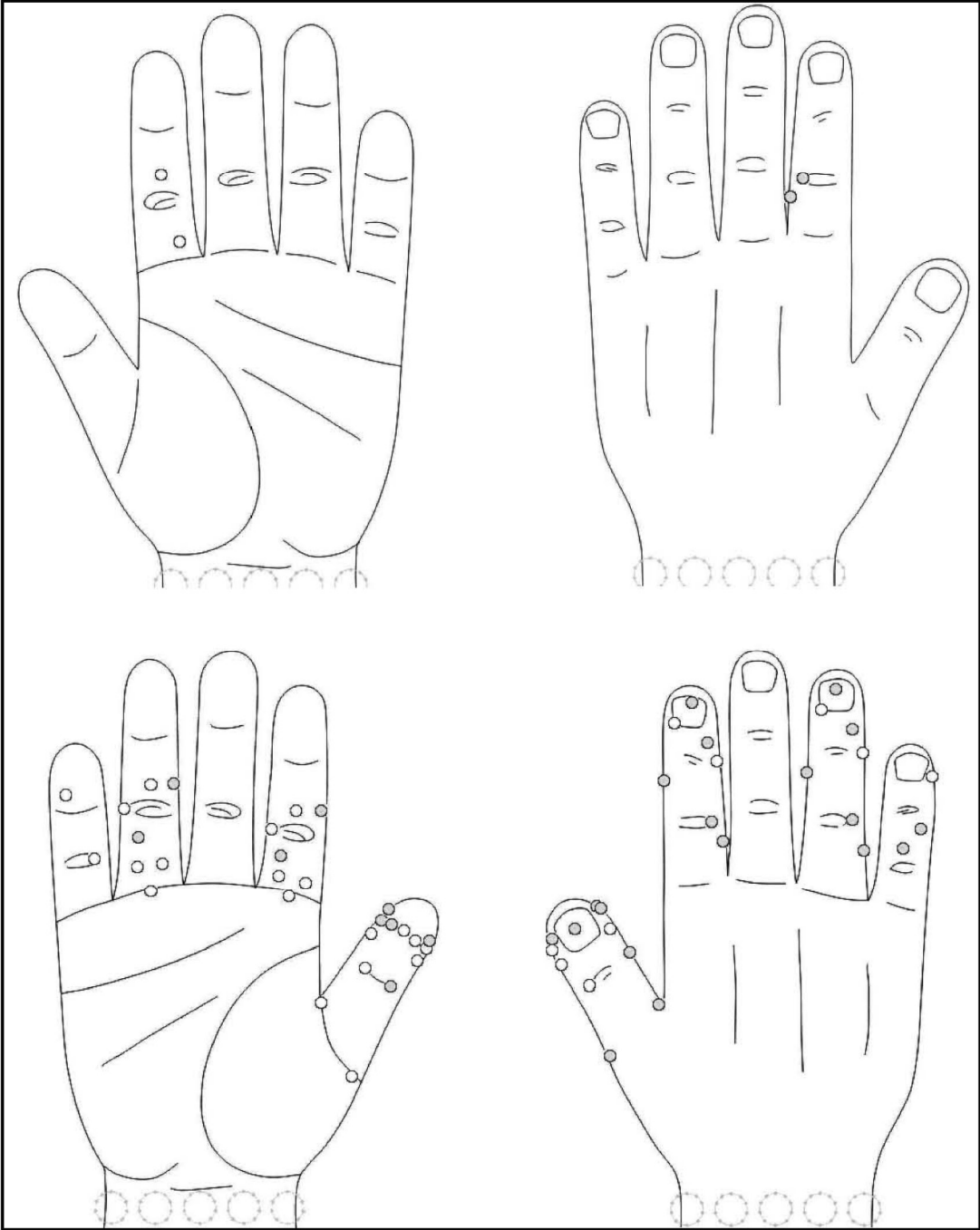
- 13.8.16
1. Pain & cold feeling in Rt lower back to foot (2yrs)
 2. Constipation (2 yrs)
 3. Gastric Problem (10 yrs)
Belching, Heaviness feeling in abdomen, Flatulence
 4. Tonsillitis (7 yrs)
 5. Rt Side Hydrocele (2011)

Treatment :

- 13.08.16
1. Rt Thumb V Jt - 2, 5 ↓ 1, 7 ↑
 2. F no. 3, 4, 5 - 3rd Spm - 2, 3 ↓ 1, 4 ↑
 3. Rt SF 5th Spm - 4, 5 ↓ 3, 7, 8 ↑
 4. Rt thumb 8 HZM

0	1	2	3	4	5	6	7	8	9
-	+	-	-	+	+	-	-	-	+
 5. Rt thumb 4/5, 3/6 RLVM - 4, 5 ↓ 3, 6 ↑ 0 ↑ 9 ↓
 6. Rt IF/RF 0 Spm - 2, 4, 5, 7, 9 ↓ 0, 1, 3, 6, 8 ↑

- Result** :
- 15.08.16
1. Relief 80%
 2. Relief 60%
 3. Relief 80%
 4. Relief 50%
 5. No Relief



Case No.- (4)

Headache & Excess vomitting After Reading

Therapist : Shri J.P. Agarwal
Patient : Samarth
Age : 6 years
Address : Mutthiganj, Allahabad
Phone : 8957948847
Symptoms :

Sleep	: 11.00 pm to 5.00 am
Thirst	: —
Urine	: —
App.	: Normal
Taste	: —
Stool	: —
Emotion	: —

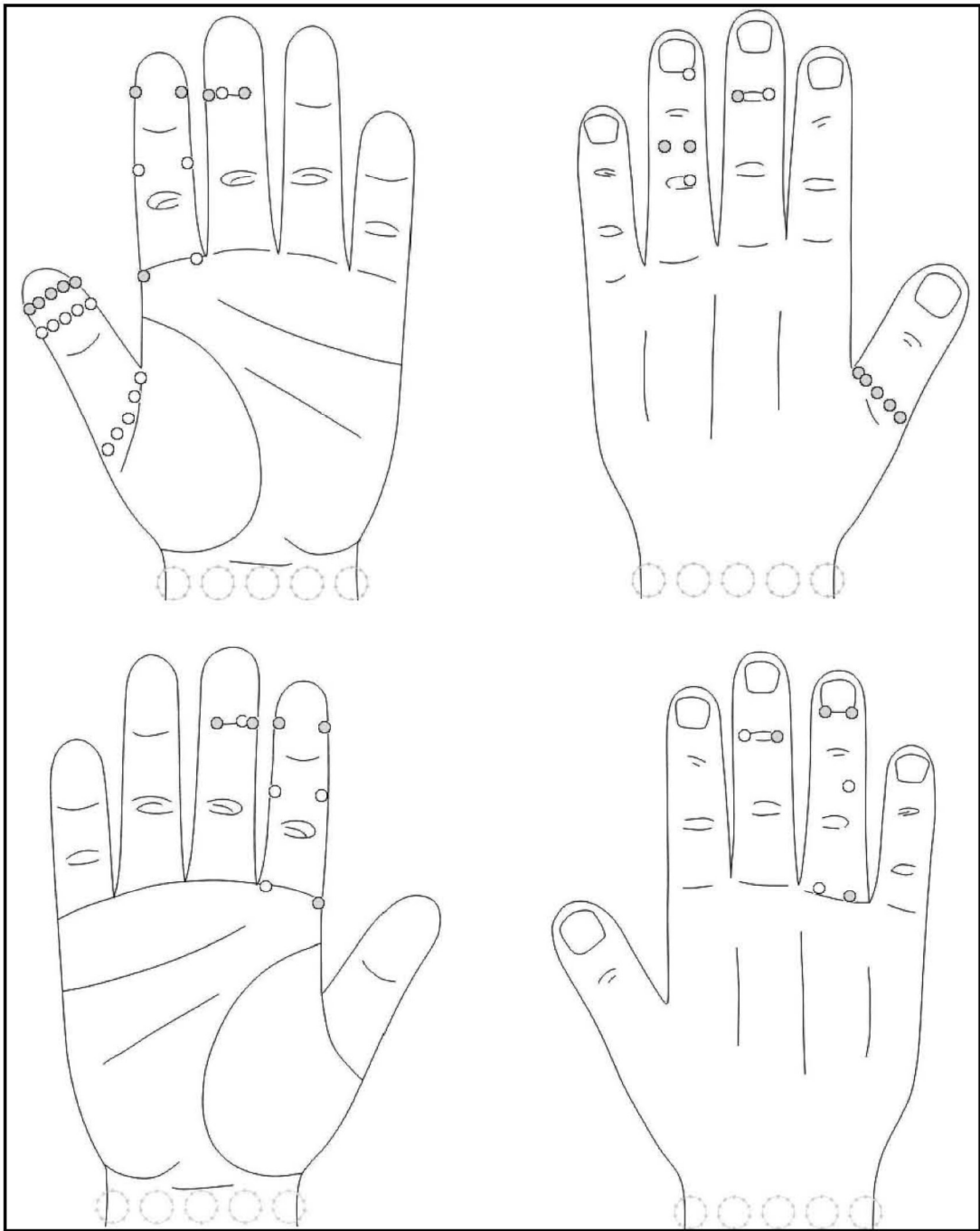
- 29.11.15
1. Headache after reading (last oct.)
 2. Exces Vomitting since oct end 26th
 3. Sometimes feverish (98'f today)
- 6.12.15
4. Watery eyes

Treatment :

- 29.11.15
1. Both IF VJt - 2, 4, 7↓ 1, 8 ↑
 2. Lt thumb all LVM - 0, 3 ↑ 4, 9 ↓
 3. Rt RF 5/6 LHM - 4, 5 ↓ 3, 6 ↑ 0 ↑ 9 ↓
Lt RF 5/6 LHM - 2, 4 ↑ 3, 6 ↓
 4. Both IF 5/6 LHM - 4, 5 ↓ 3, 6 ↑ 0 ↑ 9 ↓

Result :

- 6.12.15
1. Relief 80%
 2. Relief
 3. Relief 80%



Case No.- (5)

**Unable to Walk, Slur Speech with Blurr Vision
(Case of Brain Disorder)**

- Therapist** : J P Agrawal
- Patient** : Smt. Rashmi Saran
- Age** : 35 yrs.
- Address** : Betia, Bihar
- Phone.no** : 7903588606
- Symptoms** : 1. Rigidity in lower jaw
08.06.2016 2. Unable to walk (on wheel chair)
3. Slur speech
4. Swelling on face
5. Rigidity in right side body (Upper limb > Lower Limb)
6. Right Eye - blurred vision
7. Constipation - Chronic
- Reports** : **MRI - Whole spine screening with CEMRI cervical spine - (14 Dec 2017)**
- Straightening of cervical spine in seen.
 - Small posterior disco-osteophytic complexes are seen at C5 - C6 to C5 - C6 Level causing mild indentation of ventral thecal sac.
 - Mild degenerative changes are seen in form of small marginal osteophytes at L4 and L5 level.
 - Note is made of T2 hyperintensity in Pons and caudal midbrain which measures 25x20x18 mm in size and appear similar in size as compared to previous scan done 4 Dec 2017.
- Impression** : **Mild degenerative changes in cervical and lumbar region.**
- Contrast - Enhance MRI of brain & MR Spectroscopy - (12 Feb 2018)**
- T2/FLAIR hyperintensity in pons with linear areas of post contrast enhancement. There is thickening with mild T2/FLAIR hyperintensity and enhance in right superior peduncle.
 - Mild leptomenigeal enhancement along right side of pons.
 - On MR Spectroscopy, there is mild elevation of choline with reduced NNA peaks.

- Paranasal sinuses and mastoid air cells : Mucosal thickening in B/L ethmoid sinus. Mild DNS to right with left interior turbinate hypertrophy.
- Imaging DD Include : neurosarcoidosis/Vasculitis/CLIPPERS (Chronic lymphocytic inflammation with potine perivascular enhancement responsive to steroid).

Treatment : Humid Heat in Li & Sp

08.01.2018

1. Brain Stem correspondence (Left hand) - sedation by 10 micro magnet
2. Cerebellum correspondence (Left hand) - sedation by 10 micro magnet
3. Rt RF 5/6spm (OF) 2, 4, 5, 7, 9 ↓ 0, 1, 3, 6, 8 ↑
4. *NCH Day, date, month 1, 2, 4 ↓ 3, 5, 6 ↑
5. F.No. 3, 4, 5 - 3rd Spm 2, 3 ↓ 1, 4 ↑
6. Both SF all Ph - Cluster Magnet
7. Toe No. (0,9) 4/5, 3/6 RLVM 4, 5, ↓ 3, 6 ↑ 0 ↑ 9 ↓
8. Lt RF 5/6 LHM 2, 4 ↑ 3, 6 ↓
9. Both IF all LHM (group) 1, 4, 5 ↓ 3, 6, 8 ↑ 0 ↑ 9 ↓
10. Lt Thumb Spm³ (2, 3, 4) (OF) 1, 2, 4, 5, 7, 9 ↓ 0, 3, 6, 8 ↑

22.01.2018

11. Both IF & SF all Jts 1, 4, 5 ↓ 3, 6, 8 ↑ 0 ↑ 9 ↓
12. Rt Thumb Spm³ (0, 1, 2) NF 1, 2 ↓ 5, 6 ↑

Result : The Patient gradually responded to treatment, come in wheel chair and ultimately went to home on feet with marked improvement.

