

Case No-1**Occipitalization of atlas atlanto - axial subluxation
Strain in the Neck**

Therapist : Sri J.P Agarwal
Patient : Master Aman Mishra
Age : 12 Years
Address : Phaphamau
Phone : 9559622965
Past History : *IMP* - Cervico - Medullary Junction to C2-3 disc level suggestive of Mild Cord.edema.

MRI of Cervical Spine - 19.02.18

MR images reveal rotational subluxation of the Lt atlanto axial joint with near full thickness tear of the transvers on the Lt side (Grisel Syndrome).

Occipitalization of atlas atlanto - axial subluxation and basilar invagination.

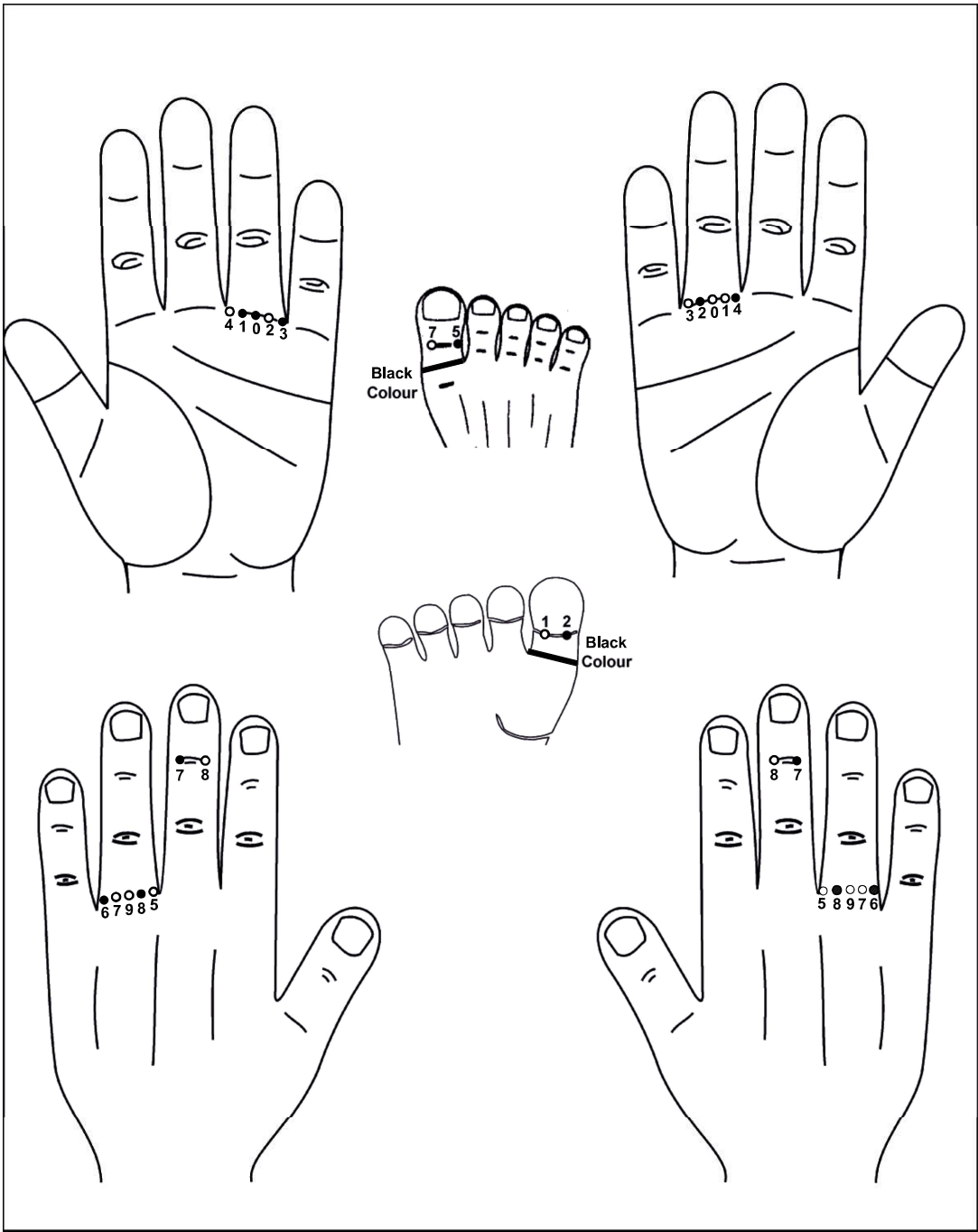
Odontoid process is displaced Superiorly and Posteriorly indenting cervico - medullary junction resulting in cord compression and mild cord-edema - is rotated approximately 30 degree anti clock wise with respect to the axis.

Symptoms : 1. Strain in the Neck can't move Lt side. (4 Month)
16.3.18 2. Neck pain and pain Radiates to occipital area.

Treatment : 1. Lt. RF Kjt – 2, 4, 5, 7, 9 ↑ 0, 1, 3, 6, 8 ↓
2. Rt. RF Kjt – 2, 4, 5, 7, 9 ↓ 0, 1, 3, 6, 8 ↑
Ring Treatment daily.

18.3.18 3. Toe No. (0) Vjt – 2, 5 ↓ 1, 7 ↑
23.3.18 4. Toe No. (0) all LVM – 0 ↑ 9 ↓ (Black Colour)
5. Both MF Vjt – 7 ↓ 8 ↑

Result 25.3.18 : 1. 60% Relief
2. 60% Relief
Relief in occipital pain



Case No-2

**Ear-Pus Formation
Bleeding Piles
Cervicle, Neck & Knee Problem**

Therapist	: Sri J.P Agarwal	Sleep	: 11/12 to 5/6
Patient	: Smt Radha Dewedi	Thirst	: Normal
Age	: 47 Years	Urine	: D-4-5
Address	: 3/2/8 Rajev bihar Navbasta, Kanpur	App.	: Normal
Phone	: 9198947265	Taste	: Sweat
		Stool	: Constipation
		Period	: Stop
		Emotion	: Happy

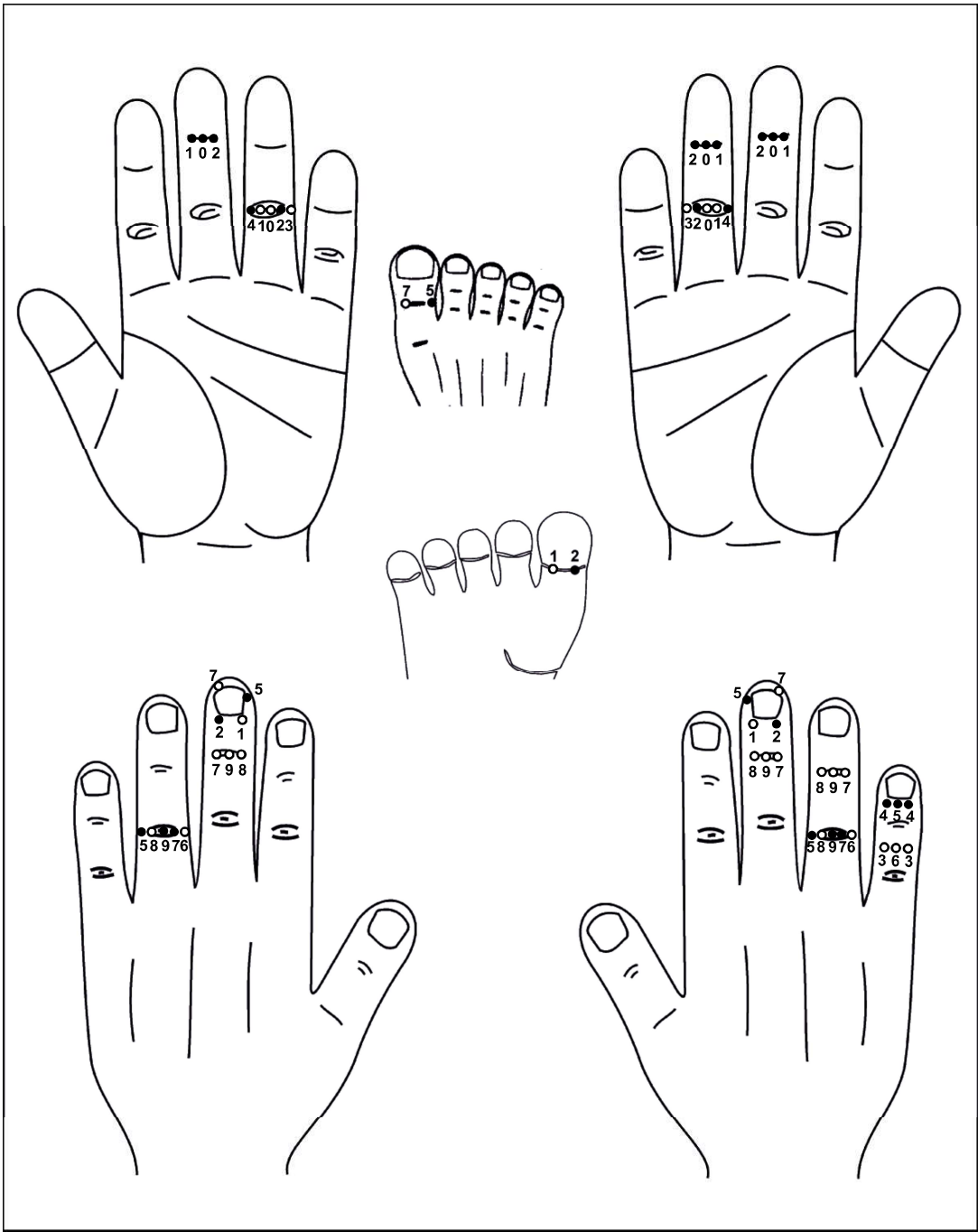
Past History

& Reports : 1.4.18 - O₂ = 98; Pulse = 66; BP = 132/72

Symptoms : 1. Cervical prob. (2 years)
1.4.18 - Neck pain radiates to Rt shoulder and scapula
2. Pain and Swelling in Rt Knee (2 years)
3. Pus formation in Rt Ear (1 year)
4. Bleeding piles (3 years)
7.4.18 5. Thyroid (on med.) (3 years)

Treatment : 1. Toe (0) Vjt - 2, 5 ↓ 1, 7 ↑
1.4.18 2. ★NCH (7 & 8) - 2, 5 ↓ 1, 7 ↑
3. Both MF Vjt - 0, 1, 2, ↓ 7, 8, 9 ↑
4. Rt SF 7/9, 8/9 RLVM - 4, 5 ↓ 3, 6 ↑
7.4.18 7. Rt RF Vjt - 0, 1, 2 ↓ 7, 8, 9 ↑
8. Both RF Pjt - 2, 4, 5, 7, 9 ↓ 0, 1, 3, 6, 8 ↑

Result 7.4.18 : 1) 10% Relief
2) 10% Relief
3) 100% Relief
4) 50% Relief



Case No-3

**Diabetese & Dibetic Neuropathy
Low Back ache thigh jt. pain etc.**

Therapist : Sri J.P Agarwal
Patient : Sunil Kumar Baranwal
Age : 50 Years
Address : Model Colony, Mithanpura Muzaferpur, Bihar
Phone : 8210529709

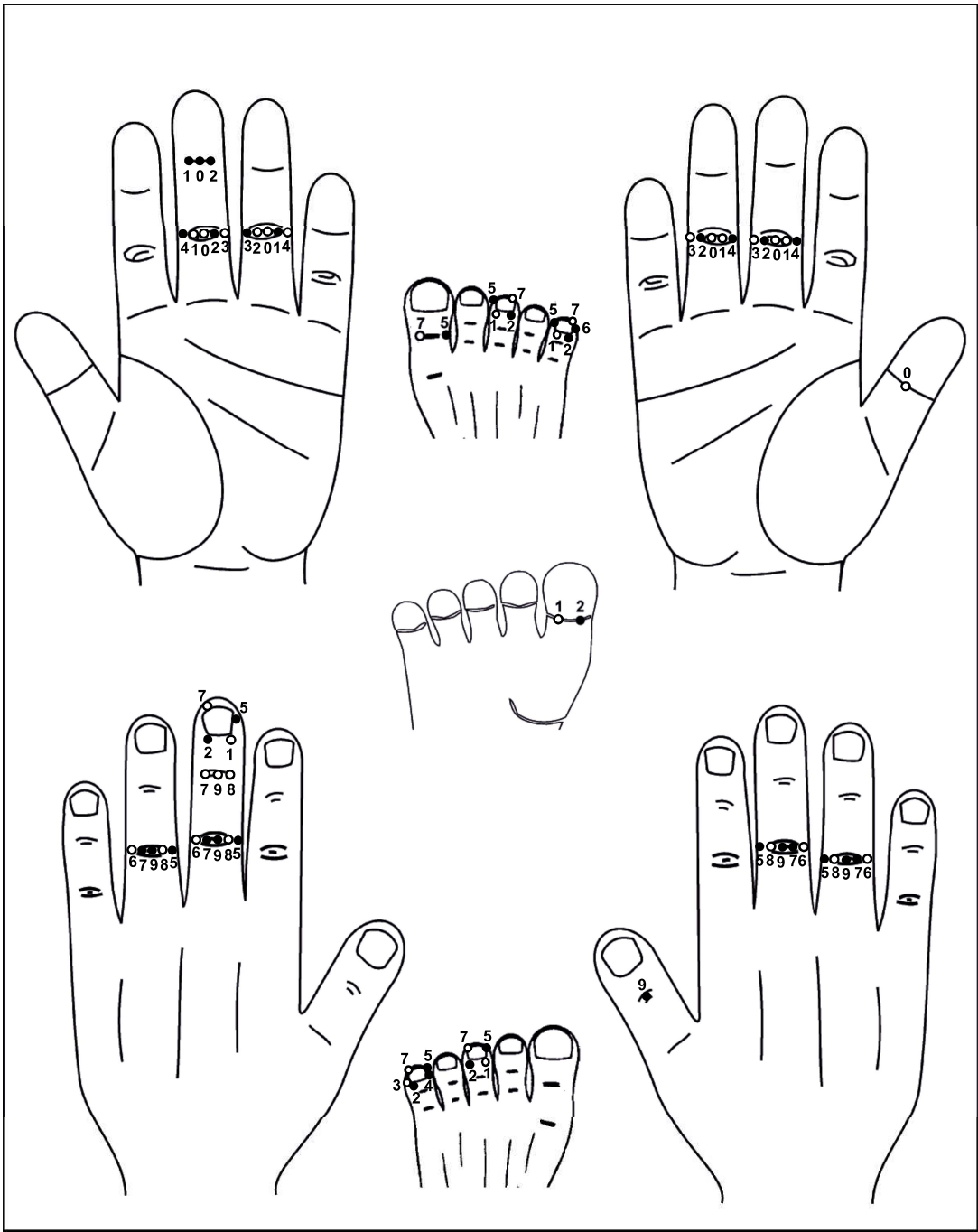
Sleep : 10/11 to 3 am
Thirst : Normal
Urine : D-5-7
App. : Normal
Taste : Salty
Stool : Normal
Emotion : Happy

Past History : Typhoid (6 Month)
PPBs 190 (2 Month); Rt leg/longer.

Symptoms : 1. Diabetes (on med.) (18 Years)
6.4.18 2. Lower back pain (14 Years)
3. Pain in Rt Thigh jt. (1 Year)
4. Piercing pain in Rt eye (1 Day)
5. Constipation (1 Day)

Treatment : 1. Toe (0) Vjt – 2, 5 ↓ 1, 7 ↑
6.4.18 2. ★NCH Toe (7 & 8) – 2, 5 ↓ 1, 7 ↑
3. Fno. 5 to 8 Pjt – 2, 4, 5, 7, 9 ↓ 0, 1, 3, 6, 8 ↑
4. ★NCH Toe (1) – 2, 5, 6 ↓ 1, 7 ↑
5. ★NCH Toe (2) – 2, 4, 5 ↓ 3, 7 ↑
7.4.18 6. Rt Thumb Vjt – 0 ↑ 9 ↓

Result 7.4.18 : 1. –
2. 80% Relief
3. 70% Relief



Case No-4

**Fatty Liver
Acidity & Gastric**

Therapist : Sri J.P Agarwal
Patient : Mr. Pankaj Diwedi
Age : 42 Years
Address : 228 A/1 Tilak Nagar Allahpur, Allahabad
Phone : 9450633301

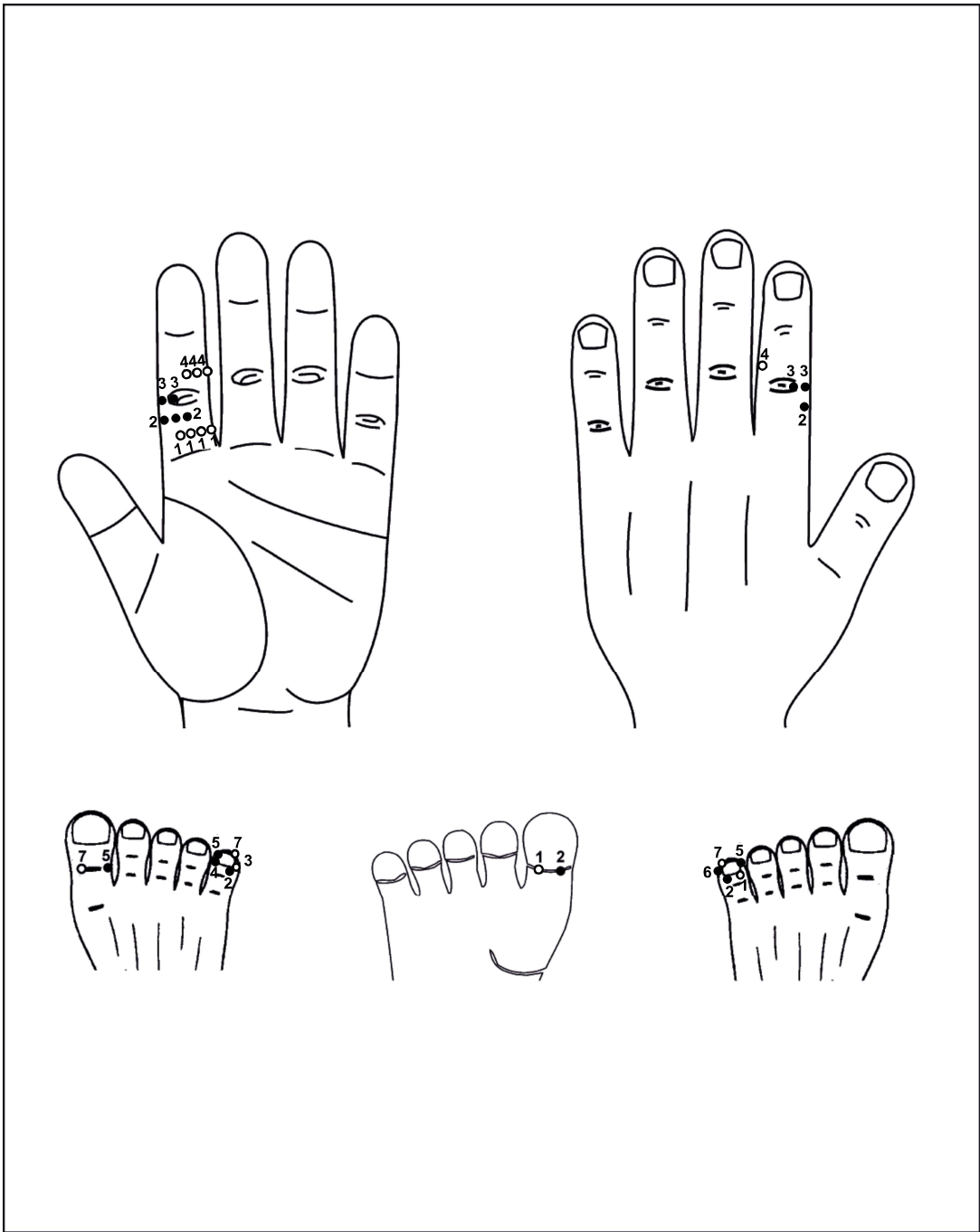
Sleep : Normal
Thirst : Low
Urine : D-3-4
App. : Normal
Taste : Salty
Stool : Constipation
Emotion : Happy

Past History : Jaundice (3 Times)
U/S (10.4.18)
IMP - Fatty Change in liver grade ?

Symptoms : 1. Constipation (10 years)
14.4.18 2. Acidity (1 month)
3. Back Pain in Lt side (8 days)
4. Excess Weight 45 kg (4 months)
5. Pitta formation (3 months)

Treatment : 1. Toe (0) Vjt - 2, 5 ↓ 1, 7 ↑
14.4.18 2. ★NCH Toe (2) - 2, 5, 6 ↓ 1, 7 ↑ } If leg longer
3. ★NCH Toe (1) - 2, 4, 5 ↓ 3, 7 ↑
4. Lt IF 0, 1, 2, 3 spr - 2, 3 ↓ 1, 4 ↑

Result 21.4.18: 1) 100% Relief
2) 100% Relief
3) 100% Relief
4) 2 kg Reduced
5) 100% Relief



Bleeding Piles

