

Case no-1

Disc Prolapse & Rectal Prolapse

*Surgical
treatment of
spine*

Therapist : Sri J.P. Agarwal

Patient : Smt. Anju Agarwal (W/O) Dr. Siddharth

Age : 54 Years

Address : Tripathi Chauraha Allahabad

Phone :

Past History : **MRI OF LUMBO SACRAL SPINE**

IMP - Lumbar Spondylosis

Focal posterocentral disc protrusion at L4/5 level causing thecal sac and cauda equina nerve root compression and mild narrowing of B/L Lateral recesses intervertebral neural foramina contributed by facet degeneration.

Broad based posterocentral and Lt paracentral disc protrusion of L5 / S1 level thecal sac and cauda equina nerve root compression and narrowing of B/L Lateral recesses and intervertebral neural foramina (L&R) contributed by facet degeneration. Fat ventral to B/L S1 nerve roots are effaced.

Associated Ligamentum flavum hypertrophy is seen.

9.8.15 O₂ - 98

PR - 68

Symptoms : 1. Disc Prolapse at L5 / S1 (1 month)

31.3.13 Severe pain radiating in Lt. Leg

2. Rectal Prolapse.

Treatment : 1. Both IF K&V Jts - 2, 4, 5, 9 ↓ 0, 3, 7 ↑

31.3.13

- (Pg.97, Charak-2, Both IF Vjt - L4 - 5)
2. Both MF P&V Jts – 2, 4, 5, 9 ↓ 0, 3, 7 ↑
(Pg.88,89, Charak-2, Both MF Vjt (L5) & Pjt (L4) Both IF - Kjt (S1))
 3. Both RF 0 Spm – 2, 4, 5 ↓ 3, 7 ↑
 4. Lt. RF 1,2,3,4,7,8 Spm – 2, 4, 5 ↓ 3, 7 ↑
(Pg.109,Charak-2, nerve divisions of 3-3)
 5. ★ RMM – 2, 4, 5, 9 ↓ 0, 3, 7 ↑
(Pg.138, Charak-2,Spine on MM)
 6. ★NCH (4,5,6,7,8) Toe – 2, 4, 5, 9 ↓ 0, 3, 7 ↑ (Pg.62, HB2- Spinal)
 7. ★NCH (5,6,7,8,9) – 2, 4, 5, 9 ↓ 0, 3, 7 ↑ (Vertebrae on NCH)
 8. Rt. SF 7/9, 8/9 RLVM – 2, 5, 9 ↓ 0, 1, 7 ↑
(Pg.194, Charak-1, division of Li - Piles)
 9. LLMM & RLMM – 2, 4, 5, 9 ↓ 1, 3, 8, 0 ↑
 10. ★ Palm 3 – ● (Gastric Problem)

Stop previous treatment

9.8.15

1. Lt. RF 1,2,7,8 Spm – 2, 4, 5 ↓ 3, 7 ↑ (Pg.109, Charak-2)
2. ★NCH (4,5,6,7,8) Toe – 2, 4, 5 ↓ 3, 7 ↑ (Pg.62, HB-2)
3. Both MF Vjts – 2, 4, 5 ↓ 3, 7 ↑ (Pg.88,89, Charak-2)
4. Both IF Kjts – 2, 4, 5 ↓ 3, 7 ↑ (Pg.88,89, Charak-2)
5. ★ Both MM – 1, 4, 5, 9 ↓ 0, 3, 6, 8 ↑
(Pg.137,138 Charak-2)
6. Rt. MF 0, 9th Spm (OF) – 4, 5 ↓ 3, 6 ↑
7. Both IF 0/1, 2/3 RLVM – 4, 5 ↓ 3, 6 ↑
(Pg.100, Dhanvantri-Knee pain)
8. ★ 7' – ● (HBP)
9. Both RF Vjts – 2, 4, 5 ↓ 3, 7 ↑ (Pg.97, Charak-2,&
10. Both RF Pjts – 2, 4, 5 ↓ 3, 7 ↑ Pg.118, HB-1)
11. Both Thumb All LVM (OF) – 4, 5, 9 ↓ 0, 3, 6 ↑ (Sending of efferent impulse from brain)

Result:

1. 70% Relief Till Pts Applied
2. NR.in Anal Prolapse

Note : still weekly treatment in continued

Case no-2

Tissue Disorder- Treatment of Diabetes, Jt pain, Leucoderma, Urine disorder, Weakness, Digestive problem

Therapist : Sri J.P Agarwal
Patient : Sri Ram Prasad Ji
Age : 75 Years
Address : Bisnapuri Colony Street no.22 Bamroli, Allahabad
Phone : 7524907079

Sleep : 11 to 5
Thirst : Less,2 Liter
Urine : D-7-8,N-8-10
App. : Normal
Taste : Normal
Stool : Constipation
Emotion : Irritation

Past History : Fasting - 95 (25.8.16)

Symptoms : 1. Both Arms - difficult to raise (3 years)
10.9.16 - Pain in Axilla region
2. Diabetes -1996 (on med)
3. Frequent Urination in night -1997
- Some time burning
4. White spot in Head, Jts in ex. - 2007
5. Constipation - (3 years)
6. Weakness - (2 month)
7. Vertigo - (1month)
25.9.16 8. Excess Bad dreams
9. Pain in Penis while passing urine

Treatment : 1. Both IF Pjts - 4, 9 ↓ 0, 2, 3 ↑(Diabetes)
10.9.16 2. Lt. IF 0 Spm - 5 ↓ 3, 4 ↑ (Hb - Deficiency)

	Rt. IF 9th Spm	-	5 ↓ 3, 4 ↑ (Hb - Deficiency)
	3. Rt.SF 5th Spm	-	4, 5 ↓ 3, 7, 8 ↑ (Constipation)
	4. Fno. (3,4,5) 3rd Spm	-	2, 3 ↓ 1, 4 ↑ (Gastric problem)
	5. Both SF all Ph	-	⊗ Star Cluster
	6. Both SF Vjt	-	2, 4, 5 ↓ 3, 7 ↑ (Both arm pain & raising problem)
	7. Both RF Kjt	-	2, 4, 5 ↓ 3, 7 ↑ (Pg.97,98 Charak-2)
	8. ★ Both MM	-	7, 9 ↓ 8 ↑ (Pg.138 Charak-2 Neck pain & vertigo)
	9. Rt. Thumb 4th Spm	-	2, 4, 7, 9 ↓ 1, 3, 6, 8 ↑ (Urine problem)
8.10.16	10. Toe no (0) 0/1, 0/2 RLVM	-	2, 4, 5, 7, 9 ↓ 0, 1, 3, 6, 8 ↑ (Urine problem/ Prostate problem)
	11. ★ 0' ↓ 0 ↓	-	⊙ (Urine problem/Prostate problem)

Result	:	1) 80% Relief (Rt.Hand)
8.10.16		- 10% Relief (Lt.Hand)
		2) Fasting - 100 PP - 150
		3) 10% Relief
		4) 10% Relief
		5) 60% Relief
		6) 60% Relief
		7) 70% Relief
		8) 50% Relief
		9) NR

Case no-3

Polio & Multiple disorders

Therapist : **Sri J.P Agarwal**
Patient : **Dr. Trisha Mishra**
Age : 38 Years
Address : Navjivan Apartment Block 'A' Sector 5 N top Hills;
Mumbai, Maharastra

Sleep : 10 to 6 Am
Thirst : Normal 3 Lit.
Urine : D-5-6,N-1-2
App. : Normal
Taste : Bitter
Stool : Constipation
Period : Timely
Emotion : Anger

Phone : 9454696575, 917738524715

Past History : DNC - 2012 (after miscarriage)
One sizarian operation 2013
IInd Sizarian operation (Dec. 2015)

Symptoms : 1. Polio in Both Legs
24.8.16 - Rt > Lt Since Childhood
2. Pain in Cervical to both Palm with tingling (5 years)
3. Lumber Pain (4 years)
4. Bodyache in morning time (4 years)
5. Bleeding Piles (5 years)
6. Constipation with gastric problem some times (5 years)
11.9.16 7. In Lt upper arm & Lt. thigh, bluish & blackish Patch (5 days)
8. Rheumatoid Arthritis

Treatment : 1. Rt. Thumb Vjt – 2, 5 ↓ 1, 7 ↑ (Pg.241 Charak-1 Navel
disturbed - 10 body holes)

- | | | |
|-------------------------|---|---|
| 2. Rt. SF 5th Spm | - | 4, 5 ↓ 3, 7, 8 ↑ (Constipation) |
| 3. Fno. (3,4,5) 3rd Spm | - | 2, 3 ↓ 1, 4 ↑ (Gastric Problem) |
| 4. Lt. RF 1,2,7,8 Spm | - | 2, 4, 5 ↓ 3, 7 ↑
(Pg.109 Charak-2, Back pain) |
| 5. Both IF All LVM | - | 4, 5, 9 ↓ 0, 3, 6 ↑
(Pg.100, Dhanwantri, Both Leg Polio) |
| 6. Rt. RF Vjt | - | 3, 4, 9 ↓ 0, 5, 6 ↑
(Pg.91, Atrey - Bleeding piles) |
| 7. Lt. RF Pjt | - | 3, 4, 9 ↓ 0, 5, 6 ↑
(Pg.90, Atrey - Bleeding piles) |
| 8. Both SF Vjt, RF Kjt | - | 2, 4, 5 ↓ 3, 7 ↑
(Pg.97,98, Charak-2 Neck to Arm pain) |
| 9. ☆ RMM | - | 2, 4, 5, 9 ↓ 0, 3, 6 ↑
(Pg.138, Charak-2 Whole Spine) |

0	1	2	3	4	5	6	7	8	9
-	+	+	-	+	+	-	-	-	+

- Result 8.10.16 :**
- 1) Much better walking
 - 2) 65% Relief
 - 3) 80% Relief
 - 4) 80% Relief
 - 5) 80% Relief
 - 6) 80% Relief
 - 7) Patches as it is
 - 8) 10% Relief

Case no-4

Tissue Disorder - Treatment of Multiple diseases

Therapist : **Sri J.P Agarwal** Sleep : 11 to 4
Patient : **Sri.Ashok Kumar Verma** Thirst : 8-9 glass
Age : 50 Years Urine : D-6-7, N-
App. : Normal
Address : 139C/30 C,lane no 22,Vishnapuri Colony,Bamroli Taste : Sweet
Emotion : Happiness

Phone : 8989844615

Past History : **Pleurisy (82-83)**

- Cured

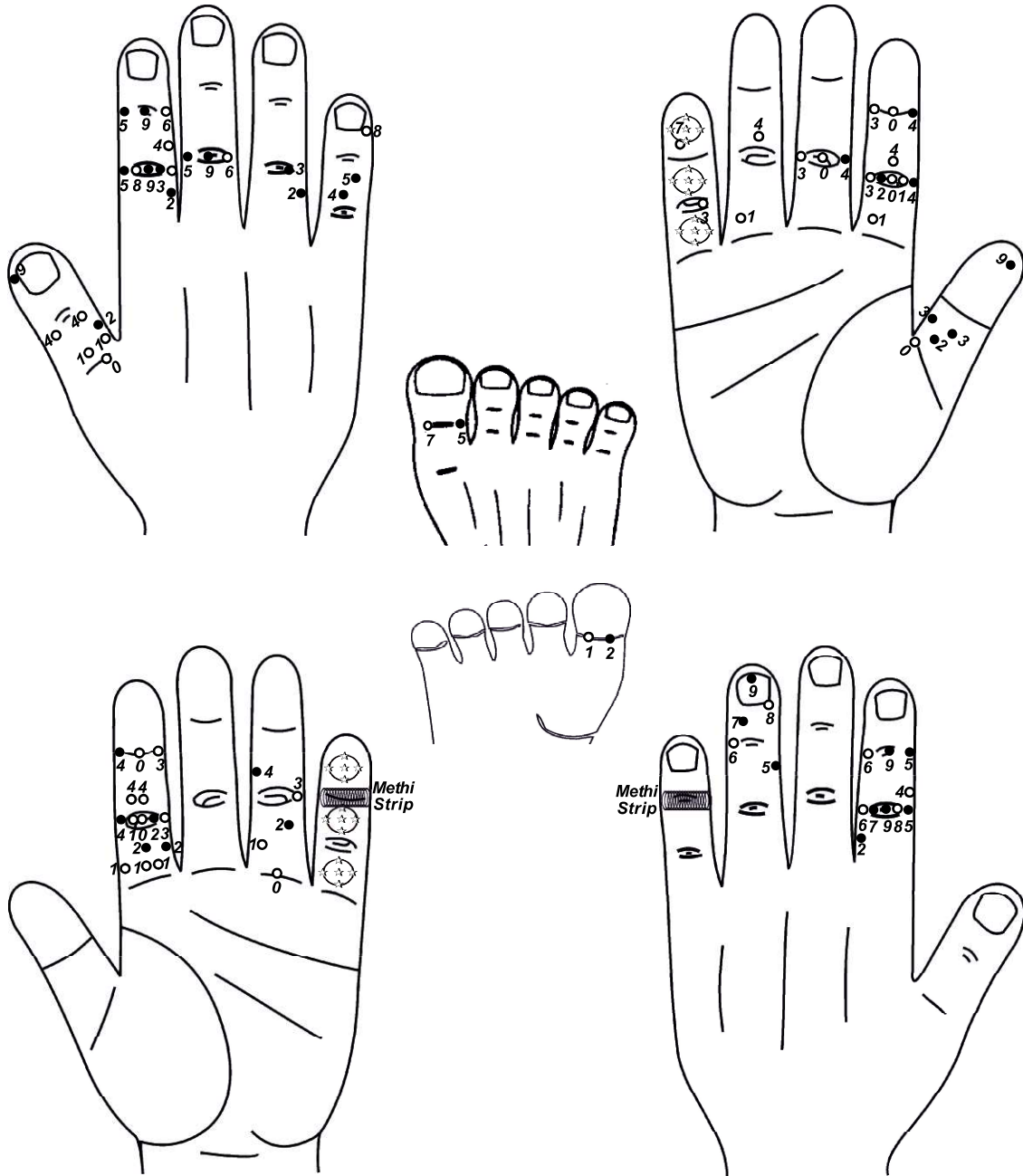
O₂ - 98

PR - 89

- Symptoms** :
1. Gastric Problem (5 month)
10.9.16 - Chest & heaviness in abdomen
- Vomiting 6-7 times in night, No. Relief in vomiting
- Problem in Passing Gas
 2. Dark Urine - yellowish (5 days)
 3. Left Shoulder pain (2 years)
 4. Blurred Vision (3 months)
 5. Rt. Knee Pain due to accident (1 year)
 6. Constipation 5-6 times
 - 18.9.16 7. Both Leg Swelling (4 years)
 8. Skin Prob.in both lower Leg & Fingers (4 years)
 - 8.10.16 9. Presbyopia (10 years)

Treatment	10.9.16	1. Rt SF 5th Spm	-	4, 5 ↓ 3, 7, 8 ↑(Constipation)
		2. Fno. 4,5 3rd Spm	-	2, 3 ↓ 1, 4 ↑(Gastric problem)
		3. Lt. IF 1,2,3 Spm	-	2, 3 ↓ 1, 4 ↑
				(Pg.94,HB - Chest pain,heaviness in abdomen)
		4. ★ Both SF All PH	-	☉ Star Cluster (Pg.91, Aatrey)
		5. Toe No 0 Vjt	-	2, 5 ↓ 1, 7 ↑
				(Pg.241, Charak-1 Navel disturbed)
		6. Both IF Vjt	-	4, 5, 9 ↓ 3, 6, 0 ↑
		7. Rt. MF Pjt	-	4, 5, 9 ↓ 3, 6, 0 ↑
				(Pg.91, Aatrey-Appendix joint -Vomiting)
		8. Lt.SF Vjt	-	Methi Strip
18.9.16		9. Rt. Thumb 8th Spm	-	2, 3, 9 ↓ 1, 4, 0 ↑(Pg.72, HB-1
		10. Rt. Thumb 4th Spm	-	2, 3, 9 ↓ 1, 4, 0 ↑ Skin problem)
2.10.16		11. Both IF Pjt	-	2, 4, 5, 7, 9 ↓ 0, 1, 3, 6, 8 ↑
				(Vision problem - Pres byopia)
8.10.16		12. Lt. RF 0 Spm	-	2, 4, 5, 7, 9 ↓ 0, 1, 3, 6, 8 ↑
				(Pg.109, Charak-2 Whole Spine)

Result	2.10.16 :	1) 60% Relief	8.10.16	1) 65%Relief
		2) 80%Relief		2) 85%Relief
		3) 75%Relief		3) 75%Relief
		4) 30%Relief		4) 85%Relief
		5) 80%Relief		5) 80%Relief
		6) 65%Relief		6) 70%Relief
		7) 55%Relief		7) 70%Relief
		8) 30%Relief		8) 40%Relief
				9) 10%Relief



Case no-5

Spine treatment of New Dimension

Therapist : **Sri J.P Agarwal** Sleep : 11 to 6 (disturbed)
Patient : **Raj Kumar Dubey** Thirst : Normal
Age : 35 Years Urine : D-8-10
Address : Hashimpur Road, Allahabad App. : Normal
Taste : Sweet
Stool : Constipation
Emotion : Normal

Phone : 9450485299

Past History : Jaundice - 2000
Typhoid - 1999
O₂ - 99 PR - 86

Symptoms : 1. Lower Mid Spine Pain (6 months)
30.9.16 - Lower back to thigh region Back side (12 days) 10 days ↑↑
2. Problem in movement
3. Constipation (10 days) - 2, 3 times, not clear

Treatment : 1. Rt SF 5th Spm - 4, 5 ↓ 3, 7, 8 ↑(Constipation)
30.9.16 2. Fno. (3,4,5)3rd Spm - 2, 3 ↓ 1, 4 ↑(Gastric problem)
3. Toe no. 0 - 1/4, 5/8 RLVM - 2, 4, 5, 7, 9 ↓ 0, 1, 3, 6, 8 ↑
(Pg.62, HB-2, Charak-2 Diagnosis)
4. Toe no. 9 - 6/7 RLVM - 2, 4, 5, 7, 9 ↓ 0, 1, 3, 6, 8 ↑
5. ★ RMM - 2, 4, 5, 9 ↓ 0, 1, 3, 6, 8 ↑
(Pg.138, Charak-2 Whole Spine)
6. Both Thumb,IF, MF VJts - 2, 4, 5, 9 ↓ 0, 3, 7 ↑(Pg.97, Charak-2
Both IF Vjt (L4-5),Pg.88,89 Charak-2, Both MF Vjt (L5)

Result 9.10.16 : 1) 70% Relief 3) 70% Relief
2) 70% Relief

